

Development of Hippocampal Functional Connectivity During Childhood

Sarah L. Blankenship,¹ Elizabeth Redcay,^{1,2}
Lea R. Dougherty,^{1,2} and Tracy Riggins^{1,2*}

¹Neuroscience and Cognitive Science Program, University of Maryland,
College Park, Maryland

²Department of Psychology, University of Maryland,
College Park, Maryland



Abstract: The hippocampus is a medial temporal lobe structure involved in memory, spatial navigation, and regulation of stress responses, making it a structure critical to daily functioning. However, little is known about the functional development of the hippocampus during childhood due to methodological challenges of acquiring neuroimaging data in young participants. This is a critical gap given evidence that hippocampally-mediated behaviors (e.g., episodic memory) undergo rapid and important changes during childhood. To address this gap, the present investigation collected resting-state fMRI scans in 97, 4- to 10-year-old children. Whole brain seed-based analyses of anterior, posterior, and whole hippocampal connectivity were performed to identify regions demonstrating stable (i.e., age-controlled) connectivity profiles as well as age-related differences in connectivity. Results reveal that the hippocampus is a highly connected structure of the brain and that most of the major components of the adult network are evident during childhood, including both unique and overlapping connectivity between anterior and posterior regions. Despite widespread age-controlled connectivity, the strength of hippocampal connectivity with regions of lateral temporal lobes and the anterior cingulate increased throughout the studied age range. These findings have implications for future investigations of the development of hippocampally-mediated behaviors and methodological applications for the appropriateness of whole versus segmented hippocampal seeds in connectivity analyses. *Hum Brain Mapp* 38:182–201, 2017. © 2016 Wiley Periodicals, Inc.

Key words: resting-state; fMRI; hippocampus; network; connectivity; development



Additional Supporting Information may be found in the online version of this article.

Contract grant sponsors: Maryland Neuroimaging Center Seed Grant Program (LRD & Dr. Luiz Pessoa; TR & ER), National Science Foundation in partnership with the University of Maryland Type: ADVANCE Program for Inclusive Excellence (LRD & TR), University of Maryland College of Behavioral and Social Sciences Dean's MRI Research Initiative RFP Program (LRD & TR; TR & ER), Behavioral and Social Sciences Dean's Research Initiative (TR & ER; LRD), Research and Scholarship Award (TR; LRD), and National Institutes of Health R01HD079518A (TR & ER).

*Correspondence to: Tracy Riggins, Department of Psychology, University of Maryland, College Park, MD 20742. E-mail: riggins@umd.edu

Received for publication 19 October 2015; Revised 9 July 2016; Accepted 9 August 2016.

DOI: 10.1002/hbm.23353

Published online 1 September 2016 in Wiley Online Library (wileyonlinelibrary.com).

INTRODUCTION

The hippocampus is a medial temporal lobe structure important for a number of critical cognitive processes including, but not limited to, episodic memory, stress regulation, and spatial navigation [Eichenbaum and Cohen, 2014; Jacobson and Sapolsky, 1991]. As such, investigations of the hippocampus and its development are important as they may provide unique insights into how neural substrates support cognition, affect, and behavior across the lifespan. For example, understanding the association between the maturation of neural circuitry and developmental changes in cognitive capacities can inform our understanding of how stimuli are represented and processed in the brain [Casey et al., 2005; Nelson et al., 2006]. Additionally, characterizing typical development allows for improvements in the ability to systematically predict, identify, and treat aberrant neural architectures early in life when their impact may have the greatest effects. Despite the broad applications for the investigation of hippocampal development, this area has received little exploration in humans.

To date, most studies investigating hippocampal development during childhood have assessed structural maturation, that is, changes in volume or morphometry. Many studies report ongoing volumetric changes in the hippocampus throughout childhood [Østby et al., 2009; Uematsu et al., 2012] and into adulthood [DeMaster et al., 2014; Giedd et al., 1996; Hu et al., 2013; Wierenga et al., 2014; Yang et al., 2013]. Although there are some inconsistencies regarding the nature and timing of hippocampal structural development across the lifespan, converging evidence demonstrates structural maturation is at least evident throughout childhood. These developmental changes are not homogeneous across the structure, as studies have shown that subregions (i.e., head, body, tail) of the hippocampus undergo differential developmental trajectories [Gogtay et al., 2006; Lin et al., 2013], which may be attributed to the distribution and development of subfields (CA1-4, dentate gyrus) along the longitudinal axis [Lavenex and Banta Lavenex, 2013]. Given the complex reciprocal relations between biological structure and function, ongoing structural changes in the size and shape of the hippocampus may be paralleled by functional changes. However, data that speak directly to functional changes during development are sparse.

The extant literature examining functional development of the hippocampus has predominantly focused on task-based activations [Chiu et al., 2006; Ghetti et al., 2010; Güler and Thomas, 2013; Ofen et al., 2007, 2012; Paz-Alonso et al., 2008, 2013; Qin et al., 2014]. Using task-based fMRI designs, researchers have demonstrated that developmental changes in hippocampal activation [Ghetti et al., 2010] and in the coordinated activity between the hippocampus and other cortical regions (i.e., connectivity) are linked to the emergence of mature episodic memory abilities and other cognitive abilities [Ofen et al., 2012; Qin

et al., 2014; for review, see Ghetti and Bunge, 2012]. Mirroring structural development during childhood, there is evidence from adults that hippocampal subregions are functionally distinct [Poppenk et al., 2013; Poppenk and Moscovitch, 2011] and that these subregions show qualitative changes in task-elicited functions during development [DeMaster et al., 2013, 2014].

Although task-based fMRI investigations are effective for studying the neural correlates of specific hippocampally-mediated processes (e.g., memory), they are limited by the nature of the experimental design (e.g., visual vs. auditory stimuli), task difficulty, and the cognitive process being studied (e.g., memory vs. spatial awareness). Thus, these studies alone do not provide sufficient evidence regarding the development of the full hippocampal network, limiting the extent to which conclusions can be drawn about functional development of the hippocampus more broadly. One method for overcoming these limitations is the use of task-independent or resting-state functional connectivity MRI (hereafter rs-fcMRI). Rs-fcMRI, first identified by Biswal et al. [1995], measures spontaneous low-frequency oscillations of brain activity while an individual lies passively in the scanner. Correlations in these low frequency oscillations are thought to be indicative of a history of co-activation, where regions demonstrating temporal coherence at rest are proposed to be the same regions that show coordinated activity during a task [Biswal et al., 1995; Power et al., 2014a, 2014b]. Therefore, rs-fcMRI permits the investigation of complex brain networks unconstrained by experimental paradigms. Moreover, given the lack of cognitive demands during scanning, rs-fcMRI makes these networks identifiable in populations who may find task demands too challenging (e.g., children, clinical patients, and older adults) [Power et al., 2010; Uddin et al., 2010a, 2010b; Vanderwal et al., 2013].

Rs-fcMRI has been successful in characterizing mature hippocampal memory networks in adults. Vincent et al. [2006] evaluated voxelwise whole-brain hippocampal connectivity using an anterior hippocampal seed to identify parietal regions uniquely connected to the hippocampal memory network and the visuo-spatial integration network and documented, across four independent datasets (total $N = 47$), a hippocampal network including medial prefrontal, posterior cingulate, and bilateral posterior parietal cortices. Others have also supported these findings and further identified hippocampal connectivity with the cerebellum, temporopolar cortex, lateral temporal cortex, striatum, anterior cingulate, angular gyrus, precentral gyrus, middle prefrontal gyrus, and superior frontal gyrus [Poppenk and Moscovitch, 2011; Uddin et al., 2010a, 2010b; Witte et al., 2014; Zhou et al., 2008]. Critically, ongoing age-related changes in hippocampal network connectivity has been associated with individual differences in memory ability in aging adults [Salami et al., 2014]. Finally, there is evidence from adults that anterior and posterior segments of the hippocampus show differential

functional connectivity throughout the cortex [Poppenk and Moscovitch, 2011]. Despite our knowledge of hippocampal connectivity in adults, little is known about the developmental changes that occur to reach this “mature” state.

Although no study to date has examined the hippocampal resting-state network in children, previous research has used rs-fcMRI to analyze other network architectures during childhood. Pediatric investigations of resting-state connectivity have recently been used to predict performance differences on behavioral tasks [Barber et al., 2013; Langeslag et al., 2013; Zhong et al., 2014], identify aberrant connectivity between patient populations [Alexander-Bloch et al., 2010; Lynch et al., 2013; Yu-Feng et al., 2007], determine general principles of network development [Fair et al., 2009; Supekar et al., 2009], and elucidate age-related differences in connectivity from subcortical regions [i.e., amgdala; Gabard-Durnam et al., 2014].

These studies highlight the usefulness of rs-fcMRI as a technique to examine functional development of structures, such as the hippocampus, where large gaps remain in our understanding. First, there is minimal research characterizing hippocampal networks in pediatric populations, leaving it unknown whether the network is similar or different than the adult network. Second, no study to date has investigated the early development of these hippocampal networks, especially during early to middle childhood (4–8 years). In fact, few resting-state studies [e.g., de Bie et al., 2012; Gabard-Durnam et al., 2014; Smyser et al., 2010] have examined network properties in awake, non-sedated children under 7 years [for review of resting-state studies in sleeping children, see Graham et al., 2015]. These are significant gaps in the literature given known changes in hippocampal structure [e.g., DeMaster et al., 2014], the rapid development of hippocampally-mediated behaviors during childhood [Bauer and Fivush, 2013; Riggins, 2014; Sluzenski et al., 2006], and evidence of ongoing processes of neural reorganization throughout adolescence and adulthood [Fair et al., 2009; Supekar et al., 2009; Purves and Lichtman, 1985] that has been proposed to influence episodic memory during childhood [Riggins et al., 2015, 2016]. Failure to understand the normal developmental trajectory of the hippocampus and its connections limits our ability to understand the mechanisms driving individual differences and age-related improvements in hippocampally-mediated cognitive and affective capacities and disorders.

The current investigation examined whole-brain seed-based hippocampal connectivity in a sample of 97 4- to 10-year-old children. We sought to identify regions demonstrating stable connectivity profiles (i.e., age-constant connectivity) as well as age-related differences in connectivity. Lastly, given evidence of functional and structural distinctions along the longitudinal axis (i.e., anterior and posterior regions in humans, ventral and dorsal segments in rodents) [DeMaster et al., 2014; Evensmoen et al., 2013; Fanselow and Dong, 2010; Kahn et al., 2008; Poppenk

et al., 2013; Poppenk and Moscovitch, 2011; Strange et al., 2014; Zeidman et al., 2014], we also investigated unique connectivity of anterior and posterior regions of the hippocampus.

METHODS

Participants

Participants in the current study were drawn from three investigations of functional and structural brain development during childhood (ages 4–10 years). Inclusionary criteria were as follows: no MR contraindications and no history of developmental disorders or previous brain injury. All studies were approved by the University of Maryland Institutional Review Board. Parents provided informed consent and children over 7 years provided written assent to participate. Participants included in the present report were selected from a larger sample ($N = 187$) based on: no movement exceeding 3 mm or degrees from the previous volume, no reports of sleeping during the functional scan, greater than 5 minutes of usable scan data after censoring (see below), and no gross structural abnormalities. If an individual participated in more than one study, the scan with the least amount of motion was included ($n = 5$). When motion was comparable, scans occurring at under-represented ages were included ($n = 1$). As seen in Figure 1, this resulted in a sample of 97 children ($M = 6.68$ years, $SD = 1.42$, range = 4.02–10.81 years; 58.8% female; 48.5% White, 23.7% African American/Black, 12.4% Multi-Racial, 3.1% Other, and 12.4% did not report; 11.3% identified as Hispanic/Latino with 14.4% choosing not to disclose; total household income ranged from <\$20,000 to >\$100,000 per year). Three participants included in the final sample were born premature at 27, 33, and 36 weeks¹. Handedness data were available for 93 individuals, only 13 of which reported being left-handed². Participants in one contributing study ($n = 43$) were recruited for an investigation of the effects of maternal depression on childhood development; of the 43 children, 27 were offspring of depressed parents³. Because history of parental depression was not screened for and thus not able to be controlled for in the other contributing studies, these participants were included in the present analyses.

Data Acquisition

All participants completed a 30–60 minute mock scanner training immediately before MR data acquisition in order

¹There were no significant differences in results when premature participants were excluded.

²There were no significant differences in results when left-handed participants were excluded.

³There were no significant differences in results when offspring of depressed parents were excluded.

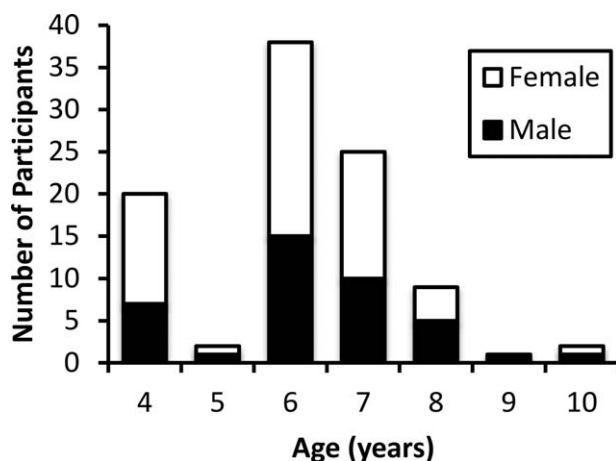


Figure 1.

Age and gender distribution of final participant sample ($n = 97$).

to become acclimated to the scanner environment and receive motion feedback. Participants were scanned in a Siemens 3.0-T scanner (MAGNETOM Trio Tim System, Siemens Medical Solutions, Erlangen, Germany) using a 12-channel coil. Before resting-state data collection, participants watched approximately 2–10 minutes of an animated film of their choice or a slideshow of still color photographs of animals in order to minimize any potential anxiety during scan set-up. All participants completed a 6-minute resting-state scan where they viewed the same video of abstract shapes (similar to a screen saver). In adults, this method does not elicit significant differences in hippocampal connectivity in comparison to a standard fixation resting-state scan, providing preliminary evidence that a non-canonical resting-state scan may be used to tap the hippocampal network without eliciting significantly altered connectivity [see Supporting Information; Greicius et al., 2003; Riggins et al., 2016; Vanderwal et al., 2015]. Functional data were collected with the following scan parameters: 180 EPI volumes consisting of 36 oblique interleaved slices with a $3.0 \times 3.0 \times 3.0$ mm voxel size; 2 s TR; 24 ms TE; 3 mm slice thickness; 90° flip angle; 64×64 pixel matrix. Structural data were collected using a high-resolution T1 magnetization-prepared rapid gradient-echo (MPRAGE) sequence consisting of 176 contiguous sagittal slices ($1.0 \times 1.0 \times 1.0$ mm voxel dimensions; 1,900 ms TR; 2.52 ms TE; 900 ms inversion time; 9° flip angle; pixel matrix = 256×256).

Pre-Processing

Functional data were slice time corrected in the Analysis of Functional Neuroimages (AFNI) software package [Cox, 1996], aligned to the first volume using rigid-body motion correction using Advanced Normalization Tools (ANTs, <http://stnava.github.io/ANTs/>), coregistered with the skull-stripped anatomical (SPM8; Wellcome Trust Centre

for Neuroimaging, London, United Kingdom), and band-pass filtered at $0.009 < f < 0.08$. Timepoints where the Euclidean distance of the derivative from the six motion parameters exceeded 1 mm were excluded, along with the previous volume, using censor files. Given convention that resting-state networks can be identified with 5 minutes of useable resting data [Power et al., 2012], participants who had less than 5 minutes of useable resting data ($n = 8$) after censoring were excluded from analyses ($M = 356.56$ seconds, $SD = 6.85$ seconds, 314–360 seconds; average number of volumes censored = 1.72). Nuisance regression included 18 regressors: five CSF and WM timeseries (left/right lateral ventricle, left/right hemisphere white matter, corpus callosum)⁴, six motion parameters and their six temporal derivatives, as well as baseline, linear, quadratic, and cubic drift. Average hippocampal timeseries were extracted from the nuisance-regressed and filtered data in native space (see below). Data were normalized with a nonlinear transformation algorithm (ANTs) to a 4.5- to 8.5-year-old symmetrical MNI Child Template [Fonov et al., 2011], selected to minimize age-related differences in image registration, then smoothed using a 6mm Gaussian kernel within a whole-brain mask. Whole brain connectivity analyses were run using 3dDeconvolve. The resulting R^2 values were converted to Pearson's r and then to z -scores using a Fisher's r -to- z transformation. Individual subjects' z -scored connectivity maps were entered into the group analysis. To control for multiple comparisons, we generated 10,000 Monte Carlo simulations using AFNI's 3dClustSim with an uncorrected voxel-wise threshold of $P = 0.001$, resulting in cluster extent $k > 25$ for $P_{corrected} < 0.05$.

Mask Generation

To ensure precise extraction of hippocampal and nuisance timeseries, individual native-space masks were generated from each participant's T1-weighted anatomical scan using an automatic segmentation procedure in FreeSurfer (surfer.nmr.mgh.harvard.edu). Resulting segmentations were visually inspected⁵, aligned with the structural and functional data, resampled to functional resolution, and converted to binary masks. Only resampled voxels which resulted in 100%, 80%, 90%, or 50% inclusion were retained in final masks for bilateral white matter, bilateral lateral ventricles, bilateral hippocampi, and corpus callosum, respectively. Each subject's bilateral hippocampal mask was split into anterior and posterior segments by identifying the last coronal slice that the uncus apex was visible, a standard anatomical landmark [Poppenk and

⁴Two individuals' lateral ventricles were too small to reliably include as a mask. For these two individuals, nuisance regression was completed without lateral ventricle timeseries.

⁵In the case of obvious under- or over-inclusions, FreeSurfer hippocampal segmentations were manually edited ($n = 8$).

Moscovitch, 2011; Weiss et al., 2005]. Final masks were visually inspected to ensure anatomical precision.

Motion

Motion has been shown to have significant deleterious effects on resting-state analyses [Power et al., 2012, 2014a, 2014b, 2015; Satterthwaite et al., 2012; Van Dijk et al., 2012]. To mitigate any potential effects of motion on our results, we took a number of precautions. (1) Only

participants who showed no more than 1 voxel (3 mm) of framewise movement throughout the entire scan were included. (2) Volumes demonstrating greater than 1 mm of framewise movement were censored in addition to the previous volume. (3) Similar to the approach reported by Gabard-Durnam et al. [2014] and suggested by Van Dijk et al. [2012] and Power et al. [2012], mean absolute framewise displacement (FD), calculated as the mean Euclidean distance between successive volumes:

$$d_i = \sqrt{(x_{i+1} - x_i)^2 + (y_{i+1} - y_i)^2 + (z_{i+1} - z_i)^2 + (\alpha_{i+1} - \alpha_i)^2 + (\beta_{i+1} - \beta_i)^2 + (\gamma_{i+1} - \gamma_i)^2}$$

was calculated for each individual and included in all analyses as a covariate. (4) To ensure that differences in movement did not account for our observed age-related effects, we demonstrated that age (in months) did not significantly correlate with mean FD ($r = -0.096$, $P = 0.348$), number of censored timepoints ($r = -0.035$, $P = 0.733$), or maximum framewise displacement ($r = -0.030$, $P = 0.773$) (Fig. 2).

Despite stringent motion inclusion criteria for such a young, movement-prone sample, our motion inclusion criteria are liberal by standards in the adult literature. Therefore, to identify regions which may have a greater likelihood of displaying false-positives in our primary analyses, we performed follow-up *t*-tests assessing differences in anterior, posterior, and whole hippocampal connectivity between median-split high and low motion groups (low motion: $M = 0.09$, $SD = 0.02$, range = 0.05–0.13; high motion: $M = 0.18$, $SD = 0.06$, range = 0.13–0.40; Supporting Information Tables 5–8). The output of these analyses was assessed for overlap with all significant regions reported below.

Age Controlled Analysis

In order to identify regions of hippocampal connectivity that were relatively stable throughout the age range being investigated, we ran an ANCOVA controlling for mean absolute displacement and age (in months), testing against 0, using the `3dttest++` function in AFNI.

Age Dependent Analysis

To identify regions where hippocampal connectivity differed linearly with age, we ran an ANCOVA using the AFNI function `3dttest++` with age (in months) as the predictor, controlling for mean absolute displacement. Age was significantly correlated with whole bilateral hippocampal connectivity with global signal ($r = 0.223$, $P = 0.028$), but not white matter ($r = -0.056$, $P = 0.584$) or CSF ($r = 0.041$, $P = 0.695$) (Fig. 3). Mean FD was not

significantly correlated with whole bilateral hippocampal connectivity with global signal ($r = 0.101$, $P = 0.326$), white matter ($r = 0.018$, $P = 0.858$) or CSF ($r = -0.105$, $P = 0.311$) (Fig. 3). Together, this suggests that observed age-related differences in hippocampal connectivity may be driven by meaningful (i.e., non-nuisance) changes in global brain activity. One possibility is that age-related increases in hippocampal-global signal connectivity may reflect ongoing changes in the hippocampus' integration with large-scale brain networks. To explore this possibility and determine how age-related changes in hippocampal connectivity may be associated with developmental changes in the involvement of the hippocampus in global brain networks, separate exploratory whole-brain connectivity analyses were conducted with regions of age-related increases in hippocampal connectivity as seed regions of interest.

Hippocampal Subregion Analysis

Given evidence that the hippocampus is a functionally heterogeneous structure [Poppenk et al., 2013; Poppenk and Moscovitch, 2011; Strange et al., 2014], and evidence that subregions show developmental change with age [DeMaster et al., 2013, 2014; Gogtay et al., 2006], we supplemented our bilateral whole hippocampal seed analyses with age-dependent and age-controlled analyses of anterior and posterior hippocampal connectivity, as described above (sections "Age controlled analysis" and "Age dependent analysis"). We employed two complementary methods to qualitatively and quantitatively assess patterns of anterior and posterior hippocampal connectivity [see Gabard-Durnam et al., 2014 for a similar approach]. The first approach, a masking technique, was employed to qualitatively highlight regions that differed in connectivity between anterior and posterior subregions in the primary analyses described above (sections "Age controlled analysis" and "Age dependent analysis"). This method was conducted by masking the thresholded (at $P < 10^{-15}$ for age-controlled, and $P < 0.05$ for age-dependent) results of the analyses of separate anterior and posterior connectivity.

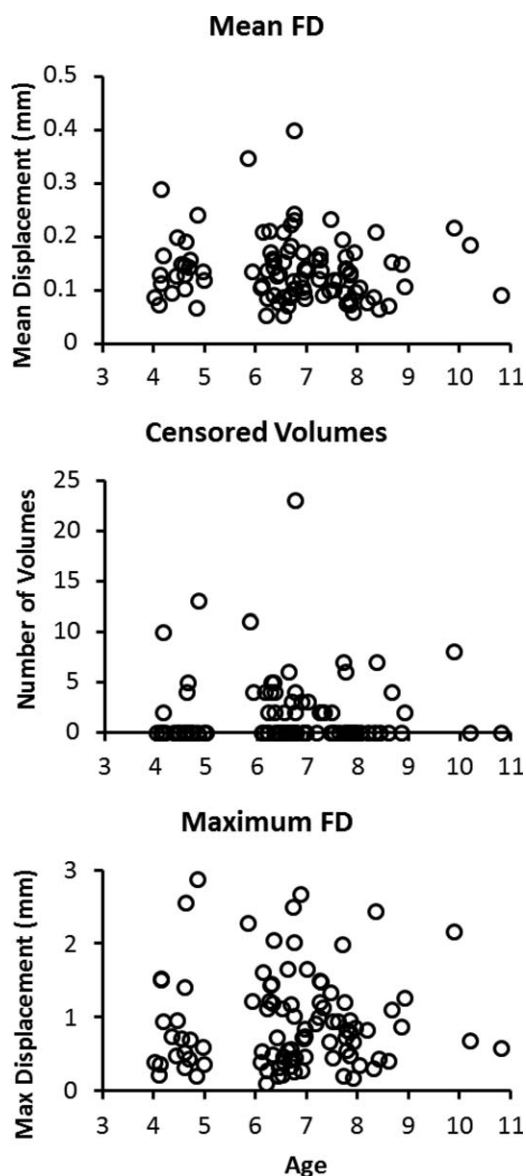


Figure 2.

Motion parameters by age. Age (in years) plotted against mean FD, number of censored volumes, and maximum movement to illustrate correlations between age and motion were not a confound in the present analyses.

Regions of map overlap (i.e., regions of connectivity with anterior and posterior connectivity) were removed to highlight regions of overlapping or unique anterior and posterior connectivity. The second approach employed a paired-samples *t*-test that tested for regions of statistically different anterior versus posterior connectivity. Together these methods provide complementary indices of regionally-specific hippocampal connectivity: the masking method provides a qualitative summary of regions with statistically significant anterior or posterior connectivity

without making claims regarding whether or not a region is more highly connected to one subregion or the other whereas the statistical approach provides a direct quantitative comparison to test for regions with statistically different anterior versus posterior connectivity.

RESULTS

Age-controlled analyses for whole hippocampus, anterior, and posterior regions, are presented first, followed by age-dependent analyses.

Age-Controlled Analyses

Whole bilateral hippocampus

At a cluster-corrected threshold of $P_{\text{corrected}} < 0.05$, most cortical gray matter was positively correlated with the hippocampal seed, with highest correlations occurring in bilateral hippocampi ($k = 59,737$). To explore these results in greater depth, the voxel-wise threshold was reduced until regions of the largest cluster segregated into distinct regions (to $P < 10^{-15}$), which largely resembled the hippocampal-parietal memory network identified in adults at rest by Vincent et al, [2006]. This hippocampal network included, but was not limited to (see Table I for entire list of included regions), regions of medial prefrontal cortex (mPFC) extending caudally through the cingulate cortex, angular gyrus extending anteriorly into supramarginal gyrus and through the temporal pole, the precuneus, and left dorsolateral prefrontal cortex (Fig. 4). Additional regions include bilateral precentral gyrus, midline subcortical structures, bilateral cerebellum, bilateral insula, and bilateral orbital cortex. There were no regions of significant negative hippocampal connectivity.

Anterior bilateral hippocampus

At the reduced voxelwise threshold ($P < 10^{-15}$) an anterior hippocampal network emerged, similar to previous reports in adults [e.g., Poppenk and Moscovitch, 2011; Vincent et al., 2006] and the whole hippocampal seed described above, including mPFC, bilateral angular gyri, precuneus, anterior and posterior cingulate, bilateral orbital cortex, bilateral temporal poles, midline subcortical structures, and cerebellum. (Table II; Fig. 4). No clusters of anterior connectivity ($k > 10$) were absent from the whole hippocampal map, suggesting that regions of whole hippocampal seed connectivity may be largely driven by anterior subfields. No regions demonstrated significant negative connectivity.

Posterior bilateral hippocampus

At the reduced voxelwise threshold, regions demonstrating age-controlled connectivity with the posterior hippocampus included: cingulate cortex, bilateral precentral gyri, angular gyrus extending into supramarginal gyrus,

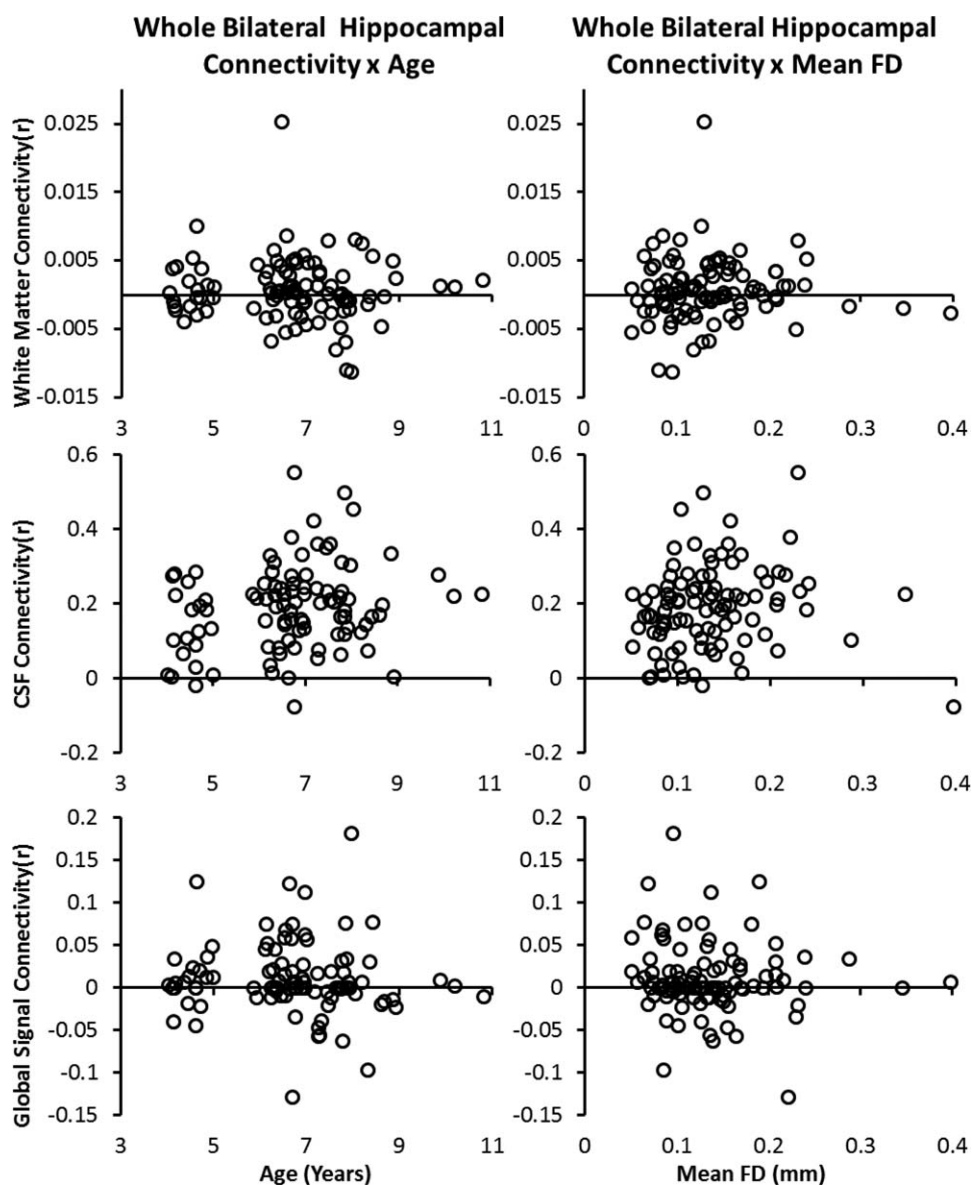


Figure 3.

Correlations between whole bilateral hippocampal connectivity with nuisance signals (i.e., white matter, CSF, and global signal) as a function of age and mean framewise displacement.

and down through the temporal pole, and cuneus (Table III; Fig. 4), all regions previously reported in adults [Poppenk et al., 2013; Poppenk and Moscovitch, 2011]. The posterior hippocampus demonstrated connectivity that was not present in analyses with the whole hippocampal seed, including connectivity with bilateral lingual gyrus, a large cluster centered in the left inferior parietal lobe and extending into the superior and middle temporal gyri, bilateral precuneus and superior cuneus, right cerebellum, and isolated regions of anterior and mid-cingulate. There were no regions of significant negative connectivity.

Unique age-controlled connectivity between anterior and posterior seeds

Whereas most regions of age-controlled connectivity overlapped between the anterior and posterior seeds, a number of regions showed unique connectivity with each subregion (Fig. 3B). As described above, two methods were used to characterize regions of unique anterior versus posterior connectivity. Using the masking approach, regions of unique anterior hippocampal connectivity included: ventromedial prefrontal cortex, medial prefrontal

TABLE I. Peak coordinates (MNI) of regions demonstrating age-independent connectivity with bilateral whole hippocampus; thresholded to voxelwise threshold of $P < 10^{-15}$, cluster-extant of 16

Region	<i>k</i>	<i>x</i>	<i>y</i>	<i>z</i>	<i>t</i>
Right Hippocampus	14,563	26	-14	-21	12.61
Bilateral Superior Medial Gyrus					
Bilateral Amygdala					
Bilateral Anterior Cingular Cortex					
Bilateral Caudate					
Bilateral Cerebellum					
Bilateral Fusiform Gyrus					
Bilateral Inferior Frontal Gyrus					
Bilateral Lingual Gyrus					
Bilateral Medial Frontal Gyrus					
Bilateral Middle Cingulate Cortex					
Bilateral Middle Temporal Gyrus					
Bilateral Parahippocampal Gyrus					
Bilateral Posterior Cingulate Cortex					
Bilateral Putamen					
Bilateral Rolandic Operculum					
Bilateral Superior Orbital Gyrus					
Bilateral Superior Temporal Gyrus					
Bilateral Temporal Pole					
Bilateral Thalamus					
Left Angular Gyrus					
Pons					
Left Precentral Gyrus	136	-43	-17	60	10.6
Right Precentral Gyrus	134	41	-14	54	10.44
Left Middle Frontal Gyrus	56	-25	28	45	10.52
Right Middle Temporal Gyrus	32	50	-56	21	10.36
Left Precentral Gyrus	26	-58	1	21	10.23

cortex, bilateral orbital cortex, left dorsolateral prefrontal cortex, a large cluster extending from inferior temporal gyrus through fusiform gyrus and down through the temporal pole, posterior cingulate, a region of precuneus, (Fig. 4). Regions of unique posterior hippocampal connectivity included a large posterior region extending from precuneus through cuneus, lingual gyrus, and down through the cerebellum, a large temporoparietal region extending from through left inferior parietal lobule, angular gyrus, and supramarginal gyrus down through superior and middle temporal gyri, right middle temporal gyrus, isolated regions of anterior, middle, and posterior cingulate cortex, bilateral regions of superior insular cortex, and regions of cerebellum (Table IV; Fig. 4).

Statistically comparing patterns of anterior and posterior connectivity revealed more localized effects than the masking approach. Regions demonstrating statistically significant greater anterior (vs. posterior) connectivity included bilateral anterior hippocampus extending rostrally to the amygdala and laterally through anterior middle temporal gyrus and fusiform gyrus, ventromedial prefrontal cortex, posterior cingulate cortex, bilateral paracentral lobule, bilateral precentral gyrus, and right orbitofrontal cortex (Table V; Fig. 4). Regions demonstrating statistically

significant greater posterior (vs. anterior) connectivity included: bilateral inferior parietal lobule extending laterally to supramarginal gyrus and angular gyrus; precuneus extending into cuneus, lingual gyrus, and cerebellum; bilateral insular cortex extending into bilateral putamen and thalamus; anterior and middle cingulate cortex; bilateral straight gyrus; bilateral dorsolateral prefrontal cortex; and left caudate (Fig. 4).

Age-Dependent Analyses

Whole bilateral hippocampus

The bilateral whole hippocampal seed showed significant age-related increases in connectivity with bilateral temporal cortex and right piriform area (Fig. 5A; Table VI). No regions demonstrated significant age-related decreases in connectivity. Regions of age-dependent connectivity with the whole hippocampal seed reflect the intersection of age-dependent connectivity in anterior and posterior seeds; therefore, follow-up investigation of the whole-brain connectivity of these seeds is included below.

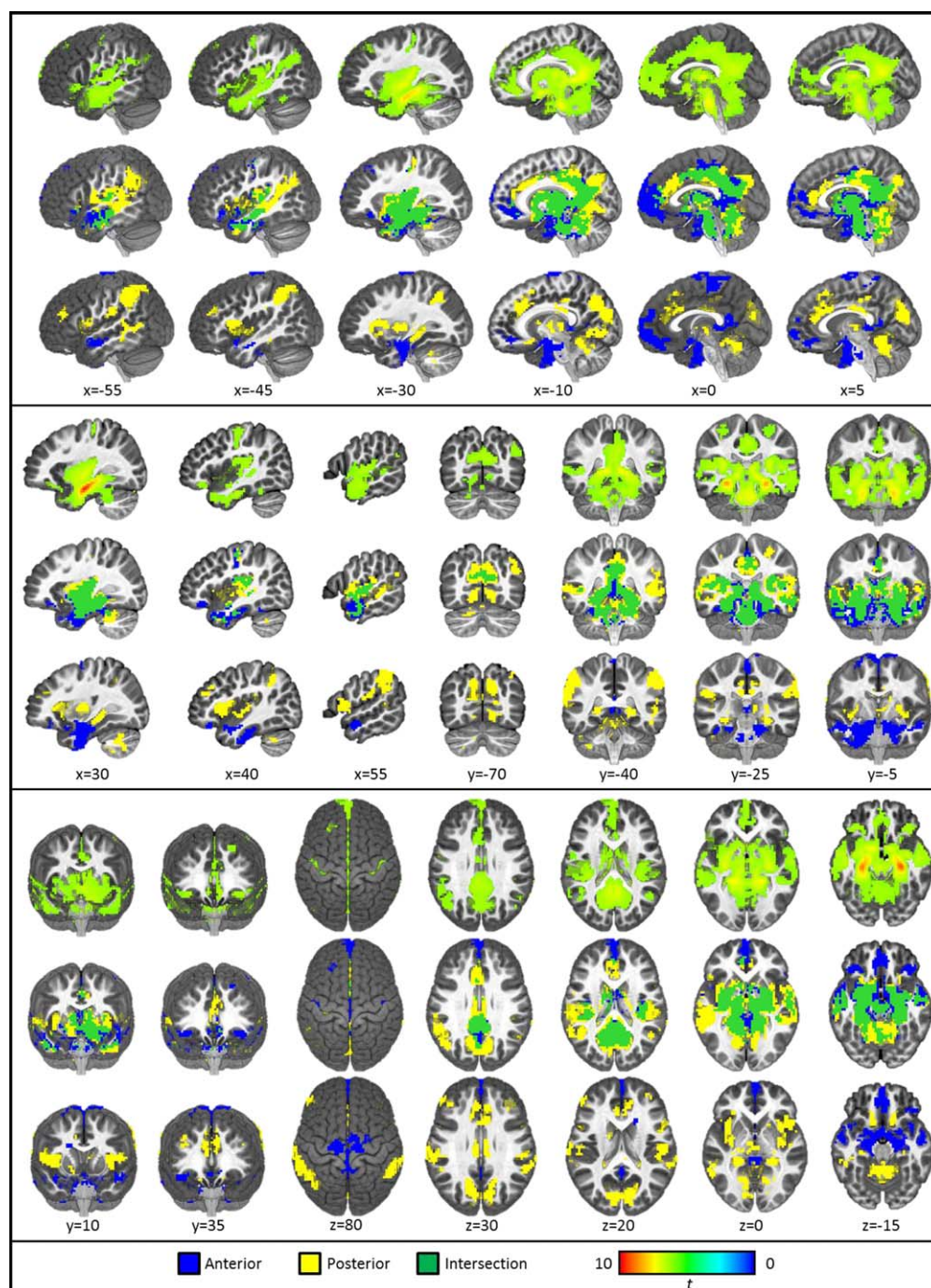


Figure 4.

Results of age-constant connectivity analyses. The first line of each panel depicts the results of the age-controlled analysis with the whole hippocampus. The second line of each panel depicts masks of unique and intersecting (green) regions of connectivity with anterior (blue) and posterior (yellow) hippocampal seeds thresholded at $P_{\text{corrected}} < 10 - 15$ (i.e., the results of the masking technique). The third row of each panel depicts the results of the quantitative anterior versus posterior

analysis revealing regions of significantly greater anterior (blue) or posterior (yellow) connectivity thresholded at $P_{\text{corrected}} < 0.05$. Sagittal views are depicted from the left slicing toward the right; Coronal views are depicted with the left hemisphere on the left; Axial views provide an aerial view of the brain with left hemisphere depicted on the right. [Color figure can be viewed at wileyonlinelibrary.com.]

TABLE II. Peak coordinates (MNI) of regions demonstrating age-independent connectivity with bilateral anterior hippocampus; thresholded to voxelwise threshold of $P < 10^{-15}$, cluster-extant of 21

Region	<i>k</i>	<i>x</i>	<i>y</i>	<i>z</i>	<i>t</i>
Right Hippocampus	9,553	26	-14	-21	12.63
Bilateral Posterior Cingulate					
Bilateral Caudate					
Bilateral Cerebellum					
Bilateral Fusiform Gyrus					
Bilateral Lingual Gyrus					
Bilateral Midbrain					
Bilateral Middle Temporal Gyrus					
Bilateral Parahippocampal Gyrus					
Bilateral Putamen					
Bilateral Superior Temporal Gyrus					
Bilateral Thalamus					
Left Inferior Frontal Gyrus (p. Orbitalis)					
Pons					
Left Mid Orbital Gyrus	651	-10	37	-12	10.76
Right Mid Orbital Gyrus					
Bilateral Anterior Cingulate Cortex					
Bilateral Superior Medial Gyrus					
Right Inferior Frontal Gyrus (p. Orbitalis)	67	38	34	-15	10.9
Left Precentral Gyrus	66	-43	-17	60	10.52
Right Precentral Gyrus	45	41	-14	54	10.22
Left Middle Frontal Gyrus	30	-25	28	45	10.27
Right Middle Temporal Gyrus	23	44	-41	3	10.43

Anterior bilateral hippocampus

Similar to results of whole hippocampal connectivity, the anterior hippocampal seed only demonstrated age-related increases in connectivity in regions isolated to left temporal lobe and right piriform cortex (Fig. 5A; Table VII). Separate exploratory whole-brain connectivity analyses were conducted with regions of age-related increases in anterior hippocampal connectivity as seeds. Results indicated that the region of left superior temporal gyrus is part of the somatomotor network (Yeo et al., 2011; Supporting Information Fig. 2B); the regions of left middle temporal gyrus and the right piriform cortex did not clearly belong to any full network at a threshold of $P < 10^{-15}$, but displayed some connectivity with regions associated with the default mode network [Raichle, 2015; Supporting Information Fig. 2A and C, respectively).

Posterior bilateral hippocampus

The posterior hippocampal seed showed age-related increases in connectivity with left angular gyrus at the temporoparietal junction, right middle temporal gyrus, and left anterior cingulate cortex (Fig. 5A; Table VIII). Separate exploratory connectivity analyses were run for each of these regions to determine brain networks with which they may be associated. All three of these regions demonstrated clear connectivity with the entire extent of the default mode network, but with greatest connectivity with

regions adjacent to the seeds. That is, the left angular gyrus demonstrated greatest connectivity to DMN parietal regions (Supporting Information Fig. 3A), the right middle temporal gyrus seed demonstrated greatest connectivity to DMN temporal regions (Supporting Information Fig. 3B), and the anterior cingulate region demonstrated greatest connectivity to frontal regions (Supporting Information Fig. 3C).

Unique age-related differences in connectivity between anterior and posterior seeds

The masking approach revealed no intersecting regions of age-related anterior or posterior hippocampal connectivity. However, there were also no regions of statistically significant age-related differences in connectivity between anterior and posterior subregions. Closer inspection of these results reveals that this apparent contradiction in results is due to similar age-related increases in connectivity with both anterior and posterior segments, with this age-related association only reaching statistical significance for one subregion in the individual statistical tests (i.e., sections “Anterior bilateral hippocampus” and “Posterior bilateral hippocampus”). Taken together, these results indicate considerable anterior/posterior overlap in age-related connectivity (see section “Overlapping connectivity” for discussion of the interpretation of overlapping connectivity).

TABLE III. Peak coordinates (MNI) of regions demonstrating age-independent connectivity with bilateral posterior hippocampus; thresholded to voxelwise threshold of $P < 10^{-15}$, cluster-extant of 21

Region	<i>k</i>	<i>x</i>	<i>y</i>	<i>z</i>	<i>t</i>
Right Hippocampus	12,661	29	-26	-12	12.06
Bilateral Anterior Cingulate Cotex					
Bilateral Amygala					
Bilateral Angular Gyrus					
Bilateral Caudate					
Bilateral Cuneus					
Bilateral Fusiform Gyrus					
Bilateral Inferior Temporal Gyrus					
Bilateral Insular Cortex					
Bilateral Lingual Gyrus					
Bilateral Middle Cingulate Cortex					
Bilateral Middle Temporal Gyrus					
Bilateral Olfactory Cortex					
Bilateral Parahippocampal Gyrus					
Bilateral Posterior Cingulate Cortex					
Bilateral Precuneus					
Bilateral Putamen					
Bilateral Superior Temporal Gyrus					
Bilateral SupraMarginal Gyrus					
Bilateral Thalamus					
Cerebellum					
Midbrain					
Pons					
Left Precentral Gyrus	69	-34	-20	48	10.32
Right Precentral Gyrus	52	35	-20	48	10.16
Right Angular Gyrus	31	53	-62	24	10.31
Left Inferior Frontal Gyrus	28	-49	19	-6	10.27

High versus low motion groups

There were no regions of age-dependent hippocampal connectivity that differed between participants in the high versus low motion groups. Similarly, no regions of age-controlled anterior, whole, or anterior versus posterior connectivity overlapped ($k > 15$) with regions differing in hippocampal connectivity between participants in the high versus low motion groups (Supporting Information Tables 5–7). However, there were regions of posterior connectivity that differed between participants in the high and low motion groups that overlapped with the age-controlled posterior hippocampal connectivity map (see section “Posterior bilateral hippocampus”). Regions of overlap included: a large region centered in the left thalamus extending laterally into the surrounding white matter and inferiorly to the subhippocampal white matter, a region of white matter superior to the left hippocampus, a region at the junction of the left fusiform gyrus and the cerebellum, a medial region of the right posterior hippocampus, the right thalamus, and the pons (Supporting Information Fig. 4). Age-controlled posterior connectivity in these regions should be interpreted with caution as they may have a particularly high susceptibility to Type I errors induced by participant motion.

DISCUSSION

The present study investigated developmental changes in hippocampal resting-state networks during early to middle childhood (4–10 years). Results revealed that the hippocampus is a highly connected subcortical structure, showing connectivity with diffuse cortical and subcortical regions. Despite widespread connectivity during childhood, age-related increases in the magnitude of connectivity were evident in a number of regions. Moreover, overlapping and unique profiles of connectivity were evident between anterior and posterior segments of the hippocampus, providing converging evidence of functional distinctions along the longitudinal axis. These findings provide some of the first measures of the development of hippocampal functional networks in childhood. The maturation of hippocampal connectivity may signal developmental changes in the efficiency or specificity of neural processing within hippocampal networks and may influence behavioral changes throughout childhood.

Age-Controlled Analyses

Age-controlled analyses, at a conservative threshold, demonstrated a hippocampal network consistent with

TABLE IV. Peak coordinates (MNI) of regions demonstrating statistically different anterior versus posterior age-independent connectivity; thresholded to voxelwise threshold of $P < 0.001$, cluster-extant of 21

Region	<i>k</i>	<i>x</i>	<i>y</i>	<i>z</i>	<i>t</i>
Anterior > Posterior					
Right Anterior Hippocampus	1,602	23	-14	-21	5.62
Left Anterior Hippocampus					
Bilateral Amygdala					
Bilateral Parahippocampal Gyrus					
Bilateral Middle Temporal Gyrus					
Bilateral Olfactory Cortex					
Bilateral Fusiform Gyrus					
Left Mid Orbital Gyrus	291	-1	58	-12	4.21
Right Mid Orbital Gyrus					
Bilateral Rectal Gyrus					
Right Posterior Cingulate Cortex	113	5	-35	3	3.99
Left Posterior Cingulate Cortex					
Left Paracentral Lobule	111	-1	-29	60	4.01
Right Precentral Gyrus	85	14	-17	78	4.17
Left Paracentral Lobule	58	-10	-14	78	4.43
Right Inferior Frontal Gyrus (p. Orbitalis)	38	44	34	-18	4.19
White Matter	23	20	10	24	3.99
Posterior > Anterior					
Right Cuneus	1631	14	-64	39	-4.21
Left Cuneus					
Bilateral Lingual Gyrus					
Bilateral Cerebellum					
Bilateral Precuneus					
Left Inferior Parietal Lobule	736	-55	-44	48	-4.5
Left SupraMarginal Gyrus					
Left Angular Gyrus					
Right Inferior Frontal Gyrus	635	47	10	6	-4.2
Right Insula					
Right Putamen					
Left Posterior Hippocampus	627	-25	-35	-3	-4.5
Left Putamen					
Bilateral Thalamus					
Left Insula					
Left Inferior Frontal Gyrus					
Right SupraMarginal Gyrus	453	59	-41	42	-4.2
Right Inferior Parietal Lobule					
Right Superior Temporal Gyrus					
Right Anterior Cingulate Cortex	184	5	34	15	-3.89
Left Middle Temporal Gyrus	139	-58	-53	3	-3.83
Left Superior Medial Cortex	137	-7	34	30	-3.88
Left Anterior Cingulate Cortex					
Right Posterior Hippocampus	108	29	-32	-9	-6.25
Left Middle Cingulate Cortex	93	-7	-17	27	-4.16
Right Middle Cingulate Cortex	80	8	-32	42	-4.17
Right Straight Gyrus	54	14	19	-15	-4.2
Right Inferior Frontal Gyrus	51	38	34	27	-3.72
Left Straight Gyrus	39	-16	25	-15	-4.44
Left Middle Frontal Gyrus	36	-52	40	21	-3.81
Left Caudate Nucleus	23	-13	1	15	-3.83

resting-state findings in adults, including regions of the medial prefrontal cortex, cingulate cortex, and lateral parietal cortex. This pattern of results suggests that the functional connections between the hippocampus and

distributed cortical and subcortical regions are apparent early in development (i.e., at least by 4 years of age). Connectivity with the whole hippocampal seed appeared to be an additive map composed of signals generated from

TABLE V. Center of mass coordinates (MNI) of regions demonstrating non-overlapping anterior or posterior connectivity derived from individual anterior or posterior connectivity analyses thresholded to voxelwise threshold of $P < 10^{-15}$, cluster-extant $k = 21$

Region	k	x	y	z
Anterior				
Pons	1,458	6	-13	-21
Bilateral Temporal Pole				
Bilateral Fusiform Gyrus				
Bilateral parahippocampal gyrus				
Bilateral Amygdala				
Bilateral Thalamus				
Left Superior Medial Gyrus	571	-1	54	2
Bilateral Rectal Gyrus				
Right Superior Medial Gyrus				
Bilateral Mid Orbital Gyrus				
Bilateral Olfactory Cortex				
Left Supplementary Motor Area	95	1	-18	51
Right Supplementary Motor Area				
Left Inferior Frontal Gyrus (p. Orbitalis)	84	-40	30	-13
Right Inferior Frontal Gyrus (p. Orbitalis)	67	41	32	-14
Left Precuneus	42	-1	-58	32
Right Precentral Gyrus	21	40	-15	42
Posterior				
Right Lingual Gyrus	2864	15	-46	4
Bilateral Posterior Cingulate Cortex				
Bilateral Cuneus				
Left Lingual Gyrus				
Bilateral Cerebellum				
Right Middle Temporal Gyrus				
Bilateral Fusiform Gyrus				
Bilateral Rolandic Operculum				
Left Superior Temporal Gyrus	1424	-48	-29	10
Left Angular Gyrus				
Left SupraMarginal Gyrus				
Left Rolandic Operculum				
Let Middle Temporal Gyrus				
Left Inferior Temporal Gyrus				
Left Insula				
Left Putamen				
Right Anterior Cingulate Cortex	275	-2	28	23
Right Putamen	58	17	13	-11
Left Inferior Temporal Gyrus	45	-41	7	-37
Right Postcentral Gyrus	33	40	-20	49
Right Caudate Nucleus	30	17	-3	16
Left Postcentral Gyrus	30	-32	-25	53
Left Thalamus	22	0	-14	-1

anterior and posterior segments. Specifically, using a masking approach, the anterior hippocampus accounted for the observed whole hippocampal connectivity with mPFC and anterolateral middle temporal gyrus, whereas posterior hippocampus accounted for the observed connectivity with the more posterior portions of the middle temporal gyrus extending through the supramarginal and angular gyri.

These effects differed in the statistical approach, which indicated that although significant connectivity may exist, neither anterior nor posterior connectivity was

significantly more connected to the most posterior portions of the middle temporal gyrus through the angular gyrus. This may be attributed to a high correlation between anterior and posterior timeseries and/or the current method for selecting statistical thresholds in the masking technique. In fact, the statistical approach suggested much more localized regions of anterior versus posterior connectivity, with anterior hippocampus projecting to medial prefrontal cortex and anterior middle temporal lobes, and the posterior hippocampus projecting to middle cingulate, bilateral insular cortex, cuneus, and

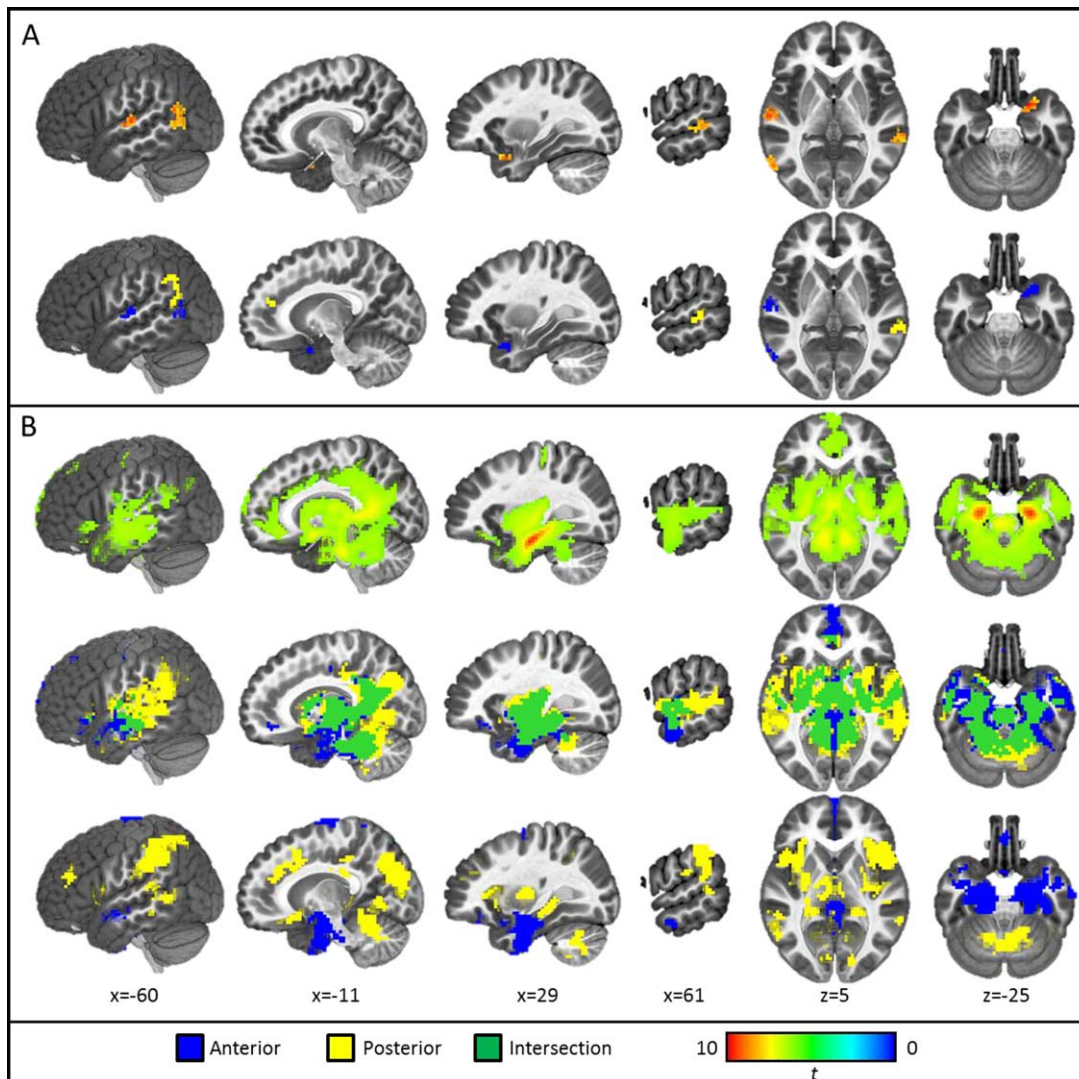


Figure 5.

Results of age-dependent connectivity analyses (A) compared with similar views from the age-controlled analysis (B). The first row of Panel A depicts regions of age-related differences in connectivity with a whole bilateral hippocampal seed. The second row of Panel A depicts masks of unique and intersecting regions of age-related connectivity with anterior and

posterior hippocampal seeds. Note: All thresholded at $P_{\text{corrected}} < 0.05$; Sagittal views are depicted from the left slicing toward the right; Axial views are presented from an aerial perspective with left hemisphere depicted on the right. [Color figure can be viewed at wileyonlinelibrary.com.]

inferior parietal lobule. These results are largely consistent with previous reports of the anterior hippocampus projecting to more anterior regions (e.g., mPFC) and posterior hippocampus projecting to cingulate cortex and parietal regions [Poppenk et al., 2013]. However, despite these consistencies, the present investigation provides new evidence that during development the anterior hippocampus demonstrates connectivity with posterior cingulate cortex. This finding may suggest more diffuse or less segregated patterns of connectivity during childhood—an established

developmental pattern [e.g., Durston et al., 2006; Fair et al., 2009; Supekar et al., 2009], which has been previously undocumented in the hippocampal network due to the limited research on this network in children.

Overlapping connectivity

Despite the fact that functional specificity is known to exist along the longitudinal axis of the hippocampus [Poppenk et al., 2013], significant overlapping anterior and

TABLE VI. Peak coordinates (MNI) of regions demonstrating age-related increases in connectivity with bilateral whole hippocampus; voxelwise threshold $P < 0.001$, cluster-extant of 16

Region	k	x	y	z	t
Left Middle Temporal Gyrus	56	-64	-59	18	3.84
Right Middle Temporal Gyrus	33	68	-35	6	3.8
Left Superior Temporal Gyrus	31	-64	-20	9	3.84
Right Piriform Cortex	26	23	10	-24	3.97
Right Periamygdaloid Cortex					

posterior connectivity was observed in age-controlled analyses in regions not previously reported as overlapping in adults. It is plausible that, in childhood, anterior and posterior regions are functionally connected to overlapping regions of cortex, as similar overlap in subregion connectivity has been demonstrated in the developing amygdala [Gabard-Durnam et al., 2014] and the adult hippocampus [Poppenk et al., 2013]. In contrast, it is also possible that central portions of the hippocampus (i.e., body) may be poorly intrinsically segregated, as has been suggested by proposals by Poppenk et al. [2013] and Moser and Moser [1998], resulting in functional gradations and overlapping connectivity driven by our methodological choice of anterior/posterior seeds. Future research would be needed to decipher between these possibilities.

Age-Dependent Analyses

Although widespread hippocampal connectivity appears to be present by age 4, the strength of some connections increased in older children. Because the results using a whole hippocampal seed mirrored the unique connectivity of anterior and posterior segments, for the sake of brevity, we will focus our discussion on the results of anterior and posterior seeds.

All regions demonstrating age-related increases in hippocampal connectivity have been previously linked to cognitive processes involving the hippocampus. For example, many temporal lobe regions have been identified as relay stations that project multimodal cortical inputs to the hippocampus for rich memory encoding [Lavenex and Amaral, 2000]. Additionally, the strength of posterior hippocampal connectivity with the right middle temporal gyrus is associated with episodic memory performance during early childhood (4–6 years) [Riggins et al., 2016]. Increasing hippocampal connectivity in more posterior

regions, including the temporoparietal junction, may reflect ongoing age-related improvements in a number of cognitive processes that are supported by both of these regions, such as: autobiographical memory retrieval, prospective, navigation, and theory of mind [Maguire and Frith, 2003; Spreng et al., 2009; Svoboda et al., 2007]. The piriform cortex and the peri-amygdaloid areas have known reciprocal connections with the ventral hippocampus in rodents (anterior hippocampus, in humans) [Eichenbaum et al., 1996] and have been implicated in the cognitive aspects of olfactory perception and odor memory [Bensafi, 2012]. The emergence of olfactory memory is established very early in life, with the majority of adult odor-cued memories generated from the childhood years (<10 years) [for review, see Larsson and Willander, 2009; Mouly and Sullivan, 2010]. Thus, the observed age-related increases in hippocampal-piriform connectivity may be linked to the importance of olfactory cues in autobiographical memory formation during childhood [Chu and Downes, 2000] versus adulthood (see Supporting Information). As a proposed site of long-term memory storage [Ross and Eichenbaum, 2006], the observed increase in anterior cingulate-hippocampal connectivity may play an important role in developmental improvements in long-term memory encoding, consolidation, and storage [Poppenk and Moscovitch, 2011; Ross and Eichenbaum, 2006] and may provide insight into the neural basis of well-documented changes in long-term memory performance during middle childhood [Ghetti and Bunge, 2012].

Follow-up connectivity analyses revealed which large-scale brain networks the regions of age-dependent connectivity belonged. Both anterior and posterior seeds were connected to the default mode network, with only the region of anterior connectivity to the left superior temporal gyrus being linked to the somatomotor network. Hippocampal involvement in the default mode network is

TABLE VII. Peak coordinates (MNI) of regions demonstrating age-related increases in connectivity with bilateral anterior hippocampus; voxelwise threshold $P < 0.001$, cluster-extant of 16

Region	k	x	y	z	t
Right Piriform Cortex	29	23	10	-24	3.96
Right Periamygdaloid Cortex					
Left Superior Temporal Gyrus	29	-64	-17	9	3.95
Left Middle Temporal Gyrus	21	-58	-65	9	3.76

TABLE VIII. Peak coordinates (MNI) of regions demonstrating age-related increases in connectivity with bilateral posterior hippocampus; voxelwise threshold $P < 0.001$, cluster-extant of 16

Region	k	x	y	z	t
Left Angular Gyrus	47	-61	-59	42	3.79
Left Inferior Parietal Lobe					
Left Middle Temporal Gyrus					
Right Middle Temporal Gyrus	34	68	-35	6	3.84
Left Anterior Cingulate Gyrus	25	2	40	24	3.61

contentious, with some studies reporting inclusion [James et al., 2013; Kaplan et al., 2016] and others reporting only the surrounding parahippocampal cortex as part of the network [Fair et al., 2008; Uddin et al., 2009; Ward et al., 2014]. The present results suggest that the hippocampus may be becoming increasingly connected to regions of the default mode network during childhood. Interestingly, regions of increased posterior hippocampal connectivity demonstrated more robust inclusion in the default mode network in comparison to regions of increased anterior hippocampal connectivity, a trend which has been documented in adults [Kim, 2015]. It is possible that the posterior hippocampus becomes more functionally integrated with the default mode network earlier than the anterior subregion. To the best of our knowledge, this is the first evidence to suggest hippocampal connectivity with the somatomotor network; studies in adults suggest the hippocampus, and medial temporal lobe more generally, operate in isolation of this network [e.g., Hayes, 2012; Kaplan et al., 2016]. The possibility of developmental changes in and relevance of hippocampal connectivity with these networks should be addressed by future research.

Due to a predominance of research investigating the memory functions of the hippocampus, less is known about how age-related increases in hippocampal connectivity may support the maturation of other known or suggested hippocampally-mediated behaviors [e.g., theory of mind; Spreng et al., 2009] or the functionality of the default mode and somatomotor networks. Future investigations are necessary for systematic identification of the behavioral relevance of the ongoing functional integration of the hippocampus with these distributed regions and broader large-scale networks.

Interestingly, not all regions of age-dependent increase in connectivity were evident in the age-controlled analyses. Specifically, the anterior hippocampus did not demonstrate connectivity with the right piriform cortex or the left middle temporal gyrus in either age-controlled analysis, suggesting these functional connections may emerge during the studied age range. In contrast, all regions of posterior hippocampal connectivity were evident in at least one of the age-controlled analysis, suggesting these connections may exist early in life and increase in strength with age. Together, these differing patterns of results from age-controlled and age-dependent analyses reveal the possible

emergence and refinement of both anterior and posterior functional connections during childhood.

Lack of Negative Associations

The current investigation found no evidence of significant negative hippocampal connectivity or decreasing connectivity with age. Previous studies that demonstrate age-constant or age-related decreases in connectivity have used a global signal regressor [Barber et al., 2013; Fair et al., 2009; Gabard-Durnam et al., 2014; Kelly et al., 2009] or had less stringent motion control [Fair et al., 2009; Gabard-Durnam et al., 2014; Power et al., 2015; Supekar et al., 2009]. The global signal regressor is, however, a contentious tool in resting-state analyses, with clear benefits to controlling for noise [Power et al., 2015], but also widely acknowledged to induce difficult-to-interpret negative correlations [Murphy et al., 2009] and evidence that removal of the global signal eliminates meaningful functional connections [Schölvinck et al., 2010]. Additionally, it is possible that there are no developmental decreases in connectivity during the narrow age-range in the current study (4–10 years) or decreases may be more variable and therefore not easily measured in terms of age-related differences.

Limitations and Future Directions

Despite strengths in examining hippocampal connectivity in a young, unexplored age range using whole and segmented hippocampal seeds, the present investigation had several limitations. First, the present investigation used a resting-state scan in which children passively viewed abstract shapes. This method was utilized as it was devoid of any overt task yet was engaging enough to minimize motion in the young sample [see Vanderwal et al., 2015 for similar approach]. Previous studies have used a similar approach in order to obtain task-independent fMRI data in young children. For example, Emerson and Cantlon [2012] examined functional connectivity from scans during which children passively viewed an educational video on “letters, numbers, and other concepts.” Critically, we report that a non-traditional low-level visual stimulation abstract shapes screen saver did not elicit significantly different hippocampal network connectivity in comparison to a fixation in a

sample of adults, providing preliminary validation for this technique in collecting resting-state data from young children. Despite no differences in the hippocampal connectivity between abstract versus fixation scans in adults, it is possible that this methodological technique (as opposed to eyes open viewing fixation or eyes closed) played a role in the present findings in children. For instance, increased attention during video viewing may have elevated hippocampal network activity, resulting in the observed whole-brain correlations or obscuring negative connectivity which may have been evident in a classic resting-state paradigm (i.e., fixation). However, the abstract shapes are not enough to explain the present results in light of the converging evidence of widespread connectivity found with the amygdala using a standard fixation [Gabard-Durnam et al., 2014], overlap of our findings with the existing rodent and adult neuroimaging literature on hippocampal networks, as well as, recent and ongoing validation of non-traditional resting-state scans [e.g., Emerson and Cantlon, 2012; Vanderwal et al., 2015].

Second, although the present investigation is the first of its kind to investigate hippocampal network development in a large sample of young children (4–10 years), the final sample includes many more children in younger age ranges (4–6 years, $n = 60$) than older ages (7–10 years, $n = 37$). This is a consequence of data compilation across three studies, each designed to examine unique research questions, but may obscure important age-related differences due to low power in the older age groups. Future investigations with wider age ranges and longitudinal designs would be beneficial to advance our current understanding of hippocampal networks.

Third, despite heeding methodological recommendations for ameliorating the effects of motion in pediatric resting-state data [see Power et al., 2012, 2014a, 2014b 2015; Satterthwaite et al., 2012; Van Dijk et al., 2012], it is possible motion contributed to the present results. For instance, at standard statistical thresholds (i.e., voxelwise threshold $P < 0.005$, $P_{\text{corrected}} < 0.05$), age-controlled analyses revealed significant hippocampal connectivity with the whole brain, which may indicate inadequate control of nuisance signals induced by motion. At stricter thresholds, a hippocampal network reminiscent of that reported in adults [Vincent et al., 2006] emerged. The ability to test these effects was likely at least partially afforded by our large original sample ($N = 187$) which enabled exclusion based on relatively conservative motion criteria while maintaining a large sample size ($n = 97$). Ongoing consideration of the appropriate motion thresholds in pediatric neuroimaging is necessary.

Despite these limitations, the present study analyzed anterior, posterior, and whole hippocampal seeds which enabled the examination of regionally-specific developmental differences in hippocampal connectivity. Although the whole hippocampus seed was largely useful in tapping connectivity of its component parts, use of the whole hippocampal seed did obscure regions of unique age-related

differences in connectivity. For instance, use of the whole hippocampal seed did not reveal age-related differences in connectivity with the left putamen; however, age-related differences in connectivity with the left putamen were evident when using the anterior seed. Future investigations of hippocampal connectivity should keep the functional heterogeneity of the hippocampus in mind when determining whether whole or segmented regions are more appropriate for examining the process of interest.

Finally, and critically, it is necessary for future investigations to examine the cognitive, affective, and behavioral relevance of the observed maturation of hippocampal connections. Specifically, a developmental perspective may provide insight into on-going debates regarding the nature of the neural computations carried out by anterior and posterior hippocampi [for extended discussion, see Poppenk and Moscovitch, 2011].

CONCLUSION

In sum, the present study was the first to investigate functional hippocampal networks in a young pediatric population. Results revealed that even in childhood the hippocampus is a highly connected subcortical structure that demonstrates functional distinctions along the longitudinal axis. In addition, both stable and age-related differences in connectivity were apparent throughout early to late childhood. Demonstration of both age-dependent and age-controlled changes in hippocampal connectivity are relevant to ongoing investigations of hippocampally-mediated cognitions and behaviors in health and disease.

ACKNOWLEDGMENTS

The authors would like to thank members of the Neurocognitive Development Lab, Developmental Social Cognitive Neuroscience Lab, Child Stress and Emotions Lab, the Laboratory of Cognition and Emotion, and the Maryland Neuroimaging Center for their contributions to this work, especially, Dr. Luiz Pessoa, Srikanth Padmala, Jason Smith, Lauren Weiss, Alan Siegel, Louis Marti, Katherine Rice, Briana Viscomi, Daniel O'Young, Amna Zehra, Jonathan Segars, Jennifer Sloane, Heather Clark, Katherine Leppert, Josh Kinnison, Mahshid Najafi, and Jennifer Stark, and the families who participated in this study.

REFERENCES

- Alexander-Bloch AF, Gogtay N, Meunier D, Birn R, Clasen L, Lalonde F, Lenroot R, Giedd J, Bullmore ET (2010): Disrupted modularity and local connectivity of brain functional networks in childhood-onset schizophrenia. *Front Syst Neurosci* 4:147.
- Barber AD, Caffo BS, Pekar JJ, Mostofsky SH (2013): Developmental changes in within- and between-network connectivity between late childhood and adulthood. *Neuropsychologia* 51:156–167.
- Bauer P, Fivush R. (2013): *The Wiley Handbook on the Development of Children's Memory*. New York: John Wiley & Sons.

- Biswal B, Yetkin FZ, Haughton VM, Hyde JS (1995): Functional connectivity in the motor cortex of resting human brain using echo-planar MRI. *Magn Reson Med* 34:537–541.
- Bensafi M (2012): The role of the piriform cortex in human olfactory perception: Insights from functional neuroimaging studies. *Chemosens Percept* 5:4–10.
- Casey BJ, Tottenham N, Liston C, Durston S (2005): Imaging the developing brain: What have we learned about cognitive development? *Trends Cogn Sci* 9:104–110.
- Chiu CYP, Schmithorst VJ, Brown RD, Holland SK, Dunn S (2006): Making memories: A cross-sectional investigation of episodic memory encoding in childhood using fMRI. *Dev Neuropsychol* 29:321–340.
- Chu S, Downes JJ (2000): Odour-evoked autobiographical memories: Psychological investigations of proustian phenomena. *Chem Senses* 25:111–116.
- Cox RW (1996): AFNI: Software for analysis and visualization of functional magnetic resonance neuroimages. *Comput Biomed Res Int J* 29:162–173.
- de Bie HMA, Boersma M, Adriaanse S, Veltman DJ, Wink AM, Roosendaal SD, Barkhof F, Stam CJ, Oostrom KJ, Delemarrevan de Waal HA, Sanz-Arigitia EJ (2012): Resting-state networks in awake five- to eight-year old children. *Hum Brain Mapp* 33:1189–1201.
- DeMaster D, Pathman T, Ghetti S (2013): Development of memory for spatial context: Hippocampal and cortical contributions. *Neuropsychologia* 51:2415–2426.
- Demaster D, Pathman T, Lee JK, Ghetti S (2014): Structural development of the hippocampus and episodic memory: Developmental differences along the anterior/posterior axis. *Cereb Cortex* 24:3036–3045.
- Durston S, Davidson MC, Tottenham N, Galvan A, Spicer J, Fossella JA, Casey BJ (2006): A shift from diffuse to focal cortical activity with development. *Dev Sci* 9:1–8.
- Eichenbaum H, Cohen NJ (2014): Can we reconcile the declarative memory and spatial navigation views on hippocampal function? *Neuron* 83:764–770.
- Eichenbaum H, Schoenbaum G, Young B, Bunsey M (1996): Functional organization of the hippocampal memory system. *Proc Natl Acad Sci* 93:13500–13507.
- Emerson RW, Cantlon JF (2012): Early math achievement and functional connectivity in the fronto-parietal network. *Dev Cogn Neurosci* 2:S139–S151.
- Evensmoen HR, Lehn H, Xu J, Witter MP, Nadel L, Håberg AK (2013): The anterior hippocampus supports a coarse, global environmental representation and the posterior hippocampus supports fine-grained, local environmental representations. *J Cogn Neurosci* 25:1908–1925.
- Fair D, Cohen AL, Dosenbach NUF, Church JA, Miezin FM, Barch DM, Raichle ME, Petersen SE, Schlaggar BL (2008): The maturing architecture of the brain's default mode network. *PNAS* 105:4028–4032.
- Fair DA, Cohen AL, Power JD, Dosenbach NU, Church JA, Miezin FM, Schlaggar BL, Petersen SE (2009): Functional brain networks develop from a “local to distributed” organization. *PLoS Comput Biol* 5:e1000381.
- Fanselow MS, Dong HW (2010): Are the dorsal and ventral hippocampus functionally distinct structures? *Neuron* 65:7–19.
- Fonov V, Evans AC, Botteron K, Almli CR, McKinstry RC, Collins DL (2011): Unbiased average age-appropriate atlases for pediatric studies. *NeuroImage* 54:313–327.
- Gabard-Durnam LJ, Flannery J, Goff B, Gee DG, Humphreys KL, Telzer E, Hare T, Tottenham N (2014): The development of human amygdala functional connectivity at rest from 4 to 23years: A cross-sectional study. *NeuroImage* 95:193–207.
- Ghetti S, Bunge S (2012): Neural changes underlying the development of episodic memory during middle childhood. *Dev Cogn Neurosci* 2:381–395.
- Ghetti S, DeMaster DM, Yonelinas AP, Bunge S. a (2010): Developmental differences in medial temporal lobe function during memory encoding. *J Neurosci* 30:9548–9556.
- Giedd JN, Vaituzis AC, Hamburger SD, Lange N, Rajapakse JC, Kaysen D, Vauss YC, Rapoport JL (1996): Quantitative MRI of the temporal lobe, amygdala, and hippocampus in normal human development: Ages 4–18 years. *J Comp Neurol* 366:223–230.
- Gogtay N, Nugent TF 3rd, Herman DH, Odonez A, Greenstein D, Hayashi KM, Clasen L, Toga AW, Giedd JN, Rapoport JL, Thompson PM (2006): Dynamic mapping of normal human hippocampal development. *Hippocampus* 16:664–672.
- Graham AM, Pfeifer JH, Fisher PA, Lin W, Gao W, Fair DA (2015): The potential of infant fMRI research and the study of early life stress as a promising exemplar. *Dev Cogn Neurosci* 12:12–39.
- Greicius MD, Krasnow B, Reiss AL, Menon V (2003): Functional connectivity in the resting brain: A network analysis of the default mode hypothesis. *Proc Natl Acad Sci U S A* 100:253–258.
- Güler OE, Thomas KM (2013): Developmental differences in the neural correlates of relational encoding and recall in children: An event-related fMRI study. *Dev Cogn Neurosci* 3:106–116.
- Hayes SM, Salat DH, Verfaellie M (2012). Default network connectivity in medial temporal lobe amnesia. *J Neurosci* 32:14622–14629.
- Hu S, Pruessner JC, Coupé P, Collins DL (2013): Volumetric analysis of medial temporal lobe structures in brain development from childhood to adolescence. *NeuroImage* 74:276–287.
- Jacobson L, Sapolsky R (1991): The role of the hippocampus in feedback regulation of the hypothalamic-pituitary-adrenocortical axis. *Endocr Rev* 12:118–134.
- James GA, Tripathi SP, Ojemann JG, Gross RE, Drane DL (2013): Diminished default mode network recruitment of the hippocampus and parahippocampus in temporal lobe epilepsy. *J Neurosurg* 119:288–300.
- Kahn I, Andrews-Hanna JR, Vincent JL, Snyder AZ, Buckner RL (2008): Distinct cortical anatomy linked to subregions of the medial temporal lobe revealed by intrinsic functional connectivity. *J Neurophysiol* 100:129–139.
- Kaplan R, Adhikari MH, Hindriks R, Mantini D, Murayama Y, Logothetis NK, Deco G (2016): Hippocampal sharp-wave ripples influence selective activation of the default mode network. *Curr Biol* 26:686–691.
- Kelly AMC, Martino A, Di Uddin LQ, Shehzad Z, Gee DG, Reiss PT, Margulies DS, Castellanos FX, Milham MP (2009): Development of anterior cingulate functional connectivity from late childhood to early adulthood. *Cereb Cortex* 19:640–657.
- Kim H (2015): Encoding and retrieval along the long axis of the hippocampus and their relationships with dorsal attention and default mode network: The HERNET model. *Hippocampus* 25:500–510.
- Langeslag SJE, Schmidt M, Ghassabian A, Jaddoe VW, Hofman A, van der Lugt A, Verhulst FC, Tiemeier H, White TJ (2013): Functional connectivity between parietal and frontal brain regions and intelligence in young children: The Generation R study. *Hum Brain Mapp* 34:3299–3307.

- Larsson M, Willander J (2009): Autobiographical odor memory. *Ann N Y Acad Sci* 1170:318–323.
- Lavenex P, Amaral DG (2000): Hippocampal-neocortical interaction: A hierarchy of associativity. *Hippocampus* 10:420–430.
- Lavenex P, Banta Lavenex P (2013): Building hippocampal circuits to learn and remember: Insights into the development of human memory. *Behav Brain Res* 254:8–21.
- Lin M, Fwu PT, Buss C, Davis EP, Head K, Muftuler LT, Sandman CA, Su M-Y (2013): Developmental changes in hippocampal shape among preadolescent children. *Int J Develop Neurosci* 31:473–481.
- Lynch CJ, Uddin LQ, Supekar K, Khouzam A, Phillips J, Menon V (2013): Default mode network in childhood autism: Postero-medial cortex heterogeneity and relationship with social deficits. *Biol Psychiatry* 74:212–219.
- Maguire EA, Frith CD (2003): Aging affects the engagement of the hippocampus during autobiographical memory retrieval. *Brain* 126:1511–1523.
- Moser MB, Moser EI (1998): Functional differentiation in the hippocampus. *Hippocampus* 8:608–619.
- Mouly A-M, Sullivan R (2010): Memory and plasticity in the olfactory system: From infancy to adulthood. In: Menini A, editor, *The Neurobiology of Olfaction*. Boca Raton, FL: CRC Press/Taylor & Francis. Chapter 15.
- Murphy K, Birn RM, Handwerker DA, Jones TB, Bandettini PA (2009): The impact of global signal regression on resting state correlations: Are anti-correlated networks introduced? *NeuroImage* 44:893–905.
- Nelson CA, Moulson MC, Richmond J (2006): How does neuroscience inform the study of cognitive development? *Hum Dev* 49: 260–272.
- Ofen N, Kao YC, Sokol-Hessner P, Kim H, Whitfield-Gabrieli S, Gabrieli JDE (2007): Development of the declarative memory system in the human brain. *Nat Neurosci* 10:1198–1205.
- Ofen N, Chai XJ, Schuil KDI, Whitfield-Gabrieli S, Gabrieli JDE (2012): The development of brain systems associated with successful memory retrieval of scenes. *J Neurosci* 32: 10012–10020.
- Østby Y, Tamnes CK, Fjell AM, Westlye LT, Due-Tønnessen P, Walhovd KB (2009): Heterogeneity in subcortical brain development: A structural magnetic resonance imaging study of brain maturation from 8 to 30 years. *J Neurosci* 29: 11772–11782.
- Paz-Alonso PM, Ghetti S, Donohue SE, Goodman GS, Bunge SA (2008): Neurodevelopmental correlates of true and false recognition. *Cereb Cortex* 18:2208–2216.
- Paz-Alonso PM, Gallego P, Ghetti S (2013): age differences in hippocampus-cortex connectivity during true and false memory retrieval. *J Int Neuropsychol Soc* 19:1031–1041.
- Poppenk J, Moscovitch M (2011): A hippocampal marker of recollection memory ability among healthy young adults: Contributions of posterior and anterior segments. *Neuron* 72:931–937.
- Poppenk J, Evensmoen HR, Moscovitch M, Nadel L (2013): Long-axis specialization of the human hippocampus. *Trends Cogn Sci* 17:230–240.
- Power JD, Fair DA, Schlaggar BL, Petersen SE (2010): The development of human functional brain networks. *Neuron* 67: 735–748.
- Power JD, Barnes KA, Snyder AZ, Schlaggar BL, Petersen SE (2012): Spurious but systematic correlations in functional connectivity MRI networks arise from subject motion. *NeuroImage* 59:2142–2154.
- Power JD, Mitra A, Laumann TO, Snyder AZ, Schlaggar BL, Petersen SE (2014a): Methods to detect, characterize, and remove motion artifact in resting state fMRI. *NeuroImage* 84: 320–341.
- Power JD, Schlaggar BL, Petersen SE (2014b): Studying brain organization via spontaneous fMRI signal. *Neuron* 84: 681–696.
- Power JD, Schlaggar BL, Petersen SE (2015): Recent progress and outstanding issues in motion correction in resting state fMRI. *NeuroImage* 105:536–551.
- Purves D, Lichtman JW (1985): *Principles of Neural Development*, 1st ed. Sunderland, Mass: Sinauer Associates.
- Qin S, Cho S, Chen T, Rosenberg-Lee M, Geary DC, Menon V (2014): Hippocampal-neocortical functional reorganization underlies children’s cognitive development. *Nat Neurosci* 17: 1263–1269.
- Raichle ME (2015): The brain’s default mode network. *Annu Rev Neurosci* 38:433–447.
- Riggins T (2014): Longitudinal investigation of source memory reveals different developmental trajectories for item memory and binding. *Dev Psychol* 50:449–459.
- Riggins T, Blankenship SL, Mulligan E, Rice K, Redcay E (2015): Developmental differences in relations between episodic memory and hippocampal subregion volume during early childhood. *Child Dev* 86:1710–1718.
- Riggins T, Geng F, Blankenship SL, Redcay E (2016): Hippocampal functional connectivity and episodic memory in early childhood. *Dev Cogn Neurosci* 19:58–69.
- Ross RS, Eichenbaum H (2006): Dynamics of hippocampal and cortical activation during consolidation of a nonspatial memory. *J Neurosci* 26:4852–4859.
- Salami A, Pudas S, Nyberg L (2014): Elevated hippocampal resting-state connectivity underlies deficient neurocognitive function in aging. *Proc Natl Acad Sci* 111:201410233.
- Satterthwaite TD, Wolf DH, Loughhead J, Ruparel K, Elliott MA, Hakonarson H, Gur RC, Gur RE (2012): Impact of in-scanner head motion on multiple measures of functional connectivity: Relevance for studies of neurodevelopment in youth. *NeuroImage* 60:623–632.
- Schölvinck ML, Maier A, Ye FQ, Duyn JH, Leopold DA (2010): Neural basis of global resting-state fMRI activity. *Proc Natl Acad Sci U S A* 107:10238–10243.
- Sluzenski J, Newcombe NS, Kovacs SL (2006): Binding, relational memory, and recall of naturalistic events: A developmental perspective. *J Exp Psychol Learn Mem Cogn* 32:89–100.
- Smyser CD, Inder TE, Shimony JS, Hill JE, Degnan AJ, Snyder AZ, Neil JJ (2010): Longitudinal analysis of neural network development in preterm infants. *Cereb Cortex* 20: 2852–2862.
- Spreng RN, Mar RA, Kim AS (2009): The common neural basis of autobiographical memory, prospection, navigation, theory of mind, and the default mode: A quantitative meta-analysis. *J Cogn Neurosci* 21:489–510.
- Strange BA, Witter MP, Lein ES, Moser EI (2014): Functional organization of the hippocampal longitudinal axis. *Nat Rev Neurosci* 15:655–669.
- Supekar K, Musen M, Menon V (2009): Development of large-scale functional brain networks in children. *PLoS Biol* 7: e1000157.
- Svoboda E, McKinnon MC, Levine B (2007): The functional neuroanatomy of autobiographical memory: A meta-analysis. *Neuropsychologia* 44:2189–2208.

- Uddin LQ, Kellye AMC, Biswal BB, Castellanos FX, Milham MP (2009): Functional connectivity of default mode network components: Correlation, anticorrelation, and causality. *Hum Brain Mapp* 30:625–637.
- Uddin LQ, Supekar K, Amin H, Rykhlevskaia E, Nguyen DA, Greicius MD, Menon V (2010a): Dissociable connectivity within human angular gyrus and intraparietal sulcus: Evidence from functional and structural connectivity. *Cereb Cortex* 20: 2636–2646.
- Uddin LQ, Supekar K, Menon V (2010b): Typical and atypical development of functional human brain networks: Insights from resting-state fMRI. *Front Syst Neurosci* 4:21.
- Uematsu A, Matsui M, Tanaka C, Takahashi T, Noguchi K, Suzuki M, Nishijo H (2012): Developmental trajectories of amygdala and hippocampus from infancy to early adulthood in healthy individuals. *PloS One* 7:e46970.
- Van Dijk KRA, Sabuncu MR, Buckner RL (2012): The Influence of Head Motion on Intrinsic Functional Connectivity MRI. *Neuroimage* 59:431–438.
- Vanderwal T, Kelly C, Castellanos FX (2013): Of Bandwagons and Bathwater: The value of resting state functional magnetic resonance imaging for child psychiatric research. *J Am Acad Child Adolesc Psychiatry* 52:562–565.
- Vanderwal T, Kelly C, Eilbott J, Mayes LC, Castellanos FX (2015): Inscapes: A movie paradigm to improve compliance in functional magnetic resonance imaging. *Neuroimage* 122:222–232.
- Vincent JL, Snyder AZ, Fox MD, Shannon BJ, Andrews JR, Raichle ME, Buckner RL (2006): Coherent spontaneous activity identifies a hippocampal-parietal memory network. *J Neurophysiol* 96:3517–3531.
- Ward AM, Schultz AP, Huijbers W, Van Dijk KR, Hedden T, Sperling RA (2014): The parahippocampal gyrus links the default-mode cortical network with the medial temporal lobe memory system. *Hum Brain Mapp* 35:1061–1073.
- Weiss AP, Dewitt I, Goff D, Ditman T, Heckers S (2005): Anterior and posterior hippocampal volumes in schizophrenia. *Schizophr Res* 73:103–112.
- Wierenga L, Langen M, Ambrosino S, van Dijk S, Oranje B, Durston S (2014): Typical development of basal ganglia, hippocampus, amygdala and cerebellum from age 7 to 24. *NeuroImage* 96:67–72.
- Witte AV, Kerti L, Margulies DS, Flöel A (2014): Effects of resveratrol on memory performance, hippocampal functional connectivity, and glucose metabolism in healthy older adults. *J Neurosci* 34:7862–7870.
- Yang X, Goh A, Chen SHA, Qiu A (2013): Evolution of hippocampal shapes across the human lifespan. *Hum Brain Mapp* 34: 3075–3085.
- Yeo BT, Krienen FM, Sepulcre J, Sabuncu MR, Lashkari D, Hollinshead M, Roffman JL, Smoller JW, Zollei L, Rolimani JR, Fischl B, Liu H, Buckner RL (2011): The organization of the human cerebral cortex estimated by intrinsic functional connectivity. *J Neurophysiol* 160:1125–1165.
- Zang YF, He Y, Zhu CZ, Cao QJ, Sui MQ, Liang M, Tian LX, Jiang TZ, Wang YF (2007): Altered baseline brain activity in children with ADHD revealed by resting-state functional MRI. *Brain Dev* 29:83–91.
- Zeidman P, Mullally SL, Maguire EA (2014): Constructing, perceiving, and maintaining scenes: Hippocampal activity and connectivity. *Cereb Cortex* 25:3836–3855.
- Zhong J, Rifkin-Graboi A, Ta AT, Yap KL, Chuang KH, Meaney MJ, Qiu A (2014): Functional networks in parallel with cortical development associate with executive functions in children. *Cereb Cortex* 24:1937–1947.
- Zhou Y, Shu N, Liu Y, Song M, Hao Y, Liu H, Yu C, Liu Z, Jiang T (2008): Altered resting-state functional connectivity and anatomical connectivity of hippocampus in schizophrenia. *Schizophr Res* 100:120–132.